

## Volumetric analysis of the pre-frontal regions: findings in aging and schizophrenia

Antonio Convit<sup>a,b,\*</sup>, Oliver T. Wolf<sup>a,1</sup>, Mony J. de Leon<sup>a,b</sup>,  
Marilou Patalinjug<sup>a</sup>, Emad Kandil<sup>a</sup>, Conrad Caraos<sup>a</sup>, Adam Scherer<sup>a</sup>,  
Les A. Saint Louis<sup>a,c</sup>, Robert Cancro<sup>a,b</sup>

<sup>a</sup>Department of Psychiatry, New York University School of Medicine, New York, NY 10016, USA

<sup>b</sup>Nathan Kline Institute for Psychiatric Research, Orangeburg, NY, USA

<sup>c</sup>Corinthian Diagnostic Radiology, New York, NY, USA

Received 9 February 2001; received in revised form 8 June 2001; accepted 13 June 2001

---

### Abstract

Frontal lobe dysfunction is thought to be involved in schizophrenia and age-associated cognitive decline. Frontal lobe volume changes have been investigated in these conditions using MRI, but results have been inconsistent. Few volumetric MRI protocols exist that divide the pre-frontal cortex into its sub-regions. In the present article, we describe a new method, which allows assessment of the superior, middle and inferior frontal gyrus, as well as the orbitofrontal and cingulate regions. The method uses multiple planes to help guide the anatomical decisions and combines this with a geometric approach utilizing readily apparent anatomical landmarks. Using this protocol, the frontal lobe volumes in young healthy subjects were contrasted with those of young schizophrenic patients and elderly healthy subjects (nine male subjects per group). The results showed that the method could be reproduced with high reliability ( $r_{icc} \geq 0.88-0.99$ ). Schizophrenic as well as old subjects had specific significant reductions in the superior frontal gyrus and orbitofrontal regions compared with the young group. However, old and schizophrenic subjects did not differ from each other. No volume differences were observed in the other three regions assessed. Whether or not these volume reductions reflect a common pathological process remains to be investigated in future studies. © 2001 Elsevier Science Ireland Ltd. All rights reserved.

**Keywords:** Frontal lobe; MRI; Volume measurement; Method; Age; Schizophrenia

---

\* Corresponding author. Center for Brain Health, Neuroimaging Laboratory, New York University School of Medicine, 560 First Avenue, HN-400, New York, NY 10016, USA. Tel.: +1-212-263-7565; fax: +1-212-263-3270.

E-mail address: antonio.convit@med.nyu.edu (A. Convit).

<sup>1</sup> Current address: Institute for Experimental Psychology II, University of Düsseldorf, Germany.

## 1. Introduction

The prefrontal cortex is central to higher cognitive functions like working memory, logical reasoning and impulse suppression (Malloy and Richardson, 1994; Smith and Jonides, 1998, 1999; West, 1996). Frontal dysfunction likely contributes to schizophrenia (Buckley, 1998; Bunney et al., 1997; Goldman-Rakic and Selemon, 1997; Velligan and Bow-Thomas, 1999), major depression (Ebert and Ebmeier, 1996; Goodwin, 1997; Lai et al., 2000) and some forms of age-associated cognitive impairment (Levin et al., 1991; Stuss and Benson, 1986; West, 1996).

The pre-frontal cortex is composed of several anatomical regions that are responsible for numerous functions including planning, language production, working memory, artistic expression, some aspects of emotional behavior and attention among others (Fuster, 1989). The human frontal lobe contains approximately 30% of the total cerebral cortical area (Uylings and Van Eden, 1990). Although it is believed that relative to other hominoids the human has frontal lobes that are proportionately larger than other brain regions, there is emerging evidence that this may not be the case (Semendeferi et al., 1997). Prefrontal cortex is most often defined as that part of the frontal lobe anterior to Brodmann's area 6 (Brodmann, 1909). The pre-frontal cortex can be divided into the dorsolateral pre-frontal cortex, the orbitofrontal cortex and the anterior cingulate cortex (Duvernoy, 1991). The dorsolateral pre-frontal cortex can be further sub-divided into the superior, middle and inferior gyri (Ono et al., 1990).

Frontal lobe dysfunction has been regarded as one of the central characteristics of schizophrenia (Andreasen et al., 1986; Goldman-Rakic and Selemon, 1997; Weinberger et al., 1986) and the volumetric assessment of frontal lobe regions has drawn considerable interest (see Lawrie and Abukmeil, 1998; McCarley et al., 1999; Pearlson and Marsh, 1999 for reviews). Previous studies utilized thick coronal slices, and consequently the sub-division of the pre-frontal cortex was rarely attempted. Therefore, these studies typically report the total volume of the pre-frontal cortex

(e.g. Breier et al., 1992; McCarley et al., 1999; Raine et al., 1992). The literature on whether or not the volume of the frontal lobe is reduced in schizophrenia remains unclear with approximately 50% of the studies reporting negative results (see McCarley et al., 1999; Pearlson and Marsh, 1999; for reviews, Wright et al., 2000 for a meta-analysis).

Neuropsychological signs of frontal lobe dysfunction are also commonly described in age-associated cognitive decline. However, only a handful of articles have examined MRI-derived frontal lobe volumes in aging cross-sectionally (Coffey et al., 1992, 1998; Wahlund et al., 1990, 1996) or longitudinally (Pfefferbaum et al., 1998; Resnick et al., 2000). Moreover, only one article described the effects of normal aging on the volume of different frontal lobe sub-regions (Raz et al., 1997).

Considering both the schizophrenia and aging research, only a few previous studies have subdivided the pre-frontal region. Examples of publications outlining previously described methods are summarized in Table 1. As can be seen in this table, methods differ substantially in the boundaries used, the number of regions assessed, and the actual reliability achieved. The lack of a uniform method to separate the prefrontal region from the adjacent pre-motor cortex has likely added to the variability in the pre-frontal region volumes reported. The separation of the pre-motor cortex from the pre-frontal region is complicated by the lack of a sulcus separating these two regions. Some previous studies have tried to separate these regions by using external landmarks (e.g. Crespo-Facorro et al., 1999; Rademacher et al., 1992; Szeszko et al., 1999; Wible et al., 1997), while others have not attempted to separate them and have included an unknown amount of pre-motor cortex in their dorsolateral pre-frontal measurements.

Today, with the routine use of thin MRI and the availability of methods to reformat and view images in multiple orientations, one can more readily make the anatomical decisions needed to sub-divide the frontal lobe (Crespo-Facorro et al., 1999; Semendeferi et al., 1997).

In order to address some of the problems of

Table 1  
Parcellation methods of the frontal region into multiple sub-regions

Method	Orientation	Slice thickness (mm)	Multi-dimensional views used	Number of sub-regions	Posterior boundary	Anterior boundary	Reliability
(Rademacher et al., 1992)	Coronal slices, perpendicular to the AC-PC line	3.1	Yes	Six	Vary by region	Vary by region	Not reported
(Berryhill et al., 1995)	Coronal slices, orientation not specified	5–8	No	Three	Last locator line on midsagittal image passing through the rostrum of C.C.	Temporal pole	0.51–0.92
(Woods et al., 1996)	Coronal slices, perpendicular to canthomeatal line	5–6, drawing done on one slice	No	Three	Genu of the C.C., based on single slice	Genu of the C.C., based on single slice	Not reported
(Wible et al., 1997)	Reformatted coronal slices, orientation not specified	1.5	Yes	Seven	3rd slice anterior to temporal stem.	Temporal pole	0.80–0.99
(Raz et al., 1997)	Coronal slices, perpendicular to AC-PC line	1.5	No	Three	Genu of C.C.	DL and OF: 40% of distance between genu of C.C. and frontal pole, Cing: 16% of the distance	Previously reported as being 0.85 and higher
(Szeszko et al., 1999)	Coronal slices, perpendicular to AC-PC line	3.1	Yes	Three	Varies by region	Varies by region	0.84–0.98
(Buchanan et al., 1998)	Coronal slices, with two orthogonal views (axial and sagittal)	1.5	Yes	Four	Varies by region	Varies by region	0.91–0.95

Table 1 (Continued)

Method	Orientation	Slice thickness (mm)	Multi-dimensional views used	Number of sub-regions	Posterior boundary	Anterior boundary	Reliability
(Baare et al., 1999)	Coronal slices, perpendicular to AC-PC	1.2	Yes	Three	Slice intersecting the posterior–superior end of pre-central sulcus, and posterior end of the rostrum.	Frontal pole	0.93
(Crespo-Facorro et al., 1999)	Coronal slices, perpendicular to AC-PC	1.5	Yes	Ten	Varies by region	Varies by region	0.86–0.99

*Abbreviations:* DL, dorsolateral region; OF, orbitofrontal region; Sup. F.G., superior frontal gyrus; Mid. F.G., middle frontal gyrus; Inf. F.G., inferior frontal gyrus; Ant. cing, anterior cingulate; C.C., corpus callosum; AC-PC line, anterior-posterior commissure line.

previously reported methods, we developed a procedure entailing a series of clearly defined anatomical decisions. Our procedure capitalizes on the ability to identify and mark specific anatomical landmarks in multiple anatomical planes (sagittal, axial and coronal) and then retain those markings in the orientation used for the volume measurements. In addition, to separate the pre-frontal cortex from the pre-motor cortex, we used a clearly defined geometric approach that utilizes readily apparent landmarks. The present article describes this newly developed method, provides data on the inter-rater reliability of the measurements and illustrates its usefulness by contrasting young normal adults with a group of age-matched schizophrenic subjects and a group of elderly normal subjects.

## 2. Methods

### 2.1. MRI evaluations

Subjects were scanned using a 1.5-T GE Advantage MR system (GE Medical Systems, Milwaukee). We obtained three sequences with a total scan time of approximately 25 min. Two sets of 3-mm-thick fast spin echo (FSE) axial images (T1- and T2-weighted) were used to ensure subjects met the inclusion and exclusion criteria. Subjects with MR evidence of infarct, hydrocephalus, intra-cranial masses or white matter lesions were excluded. White matter pathology was assessed using the modified Fazekas classification (Fazekas et al., 1987; Coffey et al., 1990), where subjects with a rating  $>2$  in either periventricular or deep-white-matter hyperintensities or subcortical-gray-matter lesions are excluded. Details of the images acquired and their parameters are described in detail elsewhere (Convit et al., 1999). For the anatomical measurements, we acquired a three-dimensional spoiled gradient recalled (SPGR) sequence in a sagittal plane. Sagittal oriented planes have the advantage of requiring fewer slices to cover the entire brain. The sagittal SPGR sequence had the following parameters: TR 35/TE 9 ms,  $60^\circ$  flip angle and one signal average; 1.2-mm slice thickness

with no gap; a 25-cm FOV; and a  $256 \times 128$  matrix resulting in a 0.98-mm in-plane pixel size. The acquisition of the sagittal scan took 9 min and contained 124 slices. These SPGR sagittal scans were used to create reformatted 2-mm-thick coronal images used for the frontal volume measurements.

### 2.2. Anatomical considerations and method

We observed considerable between-subject variability in the course of the major frontal lobe sulci. However, the combined use of the sagittal, axial and coronal views results in high inter-observer agreement for the determination of those sulci. In addition, for those cases where the superior or inferior frontal sulci are either not continuous or run in an atypical orientation, using the distribution of gyral white matter across multiple coronal images [as suggested by Iwasaki et al. (1991) for the pre- and post-central gyri] greatly improves their determination.

In order to carry out the frontal lobe volume measurements, we go through a series of steps, each of which will be described in turn. The steps are: (i) separately for each hemisphere, identify the anterior and posterior boundaries for the frontal regions to be measured; (ii) separately for each hemisphere, identify and mark on sagittal and axial images landmarks needed to sub-divide the frontal lobe; (iii) create a standard reformatted coronal image; (iv) transpose those markings to the standardized coronal reformatted images used for the volume measurements; and (v) separately for each hemisphere, on the coronal reformatted image containing the transposed markings, define an 'anchor point' from which the regions of interest (ROIs) are drawn.

- **Identify the anterior and posterior boundaries for the frontal regions to be measured:** as seen on Fig. 1, we divide the frontal lobe, from the anterior pole to the pre-central sulcus (pcs) into several major regions: the motor (MC) and supplementary motor region (SM); the pre-frontal region (PF); and the frontal pole (FP). The pre-frontal region is bounded anteriorly by the frontal pole and posteriorly by

the anterior margin of the supplementary motor cortex. We differentiate the pre-frontal cortex from the supplementary motor (SM) region geometrically, using as a boundary the coronal plane that bisects the distance between the cingulate sulcus and the pre-central sulcus in two equal parts (Fig. 1). This produces a supplementary motor cortex seen as an inverted triangular wedge of tissue anterior to the pre-central sulcus (pcs). This definition of the supplementary motor region was based on our examination of the Brodmann maps (Brodmann, 1909). The resulting pre-frontal region is further separated into the superior (SFG), middle (MFG), inferior (IFG) frontal gyri and the orbitofrontal (OF) region. The

frontal opercular (Broca) region, which includes pars opercularis, triangularis and orbitalis, is considered part of the inferior frontal gyrus. Our definition of the orbital region includes the orbital and rectal gyri. The frontal pole is defined as the brain tissue anterior to the cingulate sulcus (cs). When there is a double parallel type of cingulate sulcus, as occurs in 24% of cases (Ono et al., 1990), the most posterior is chosen. The cingulate is defined as the region contained between the cingulate and pericallosal sulci.

- **Identify and mark relevant anatomical landmarks to create the frontal sub-regions:** it is difficult to identify the boundary between the

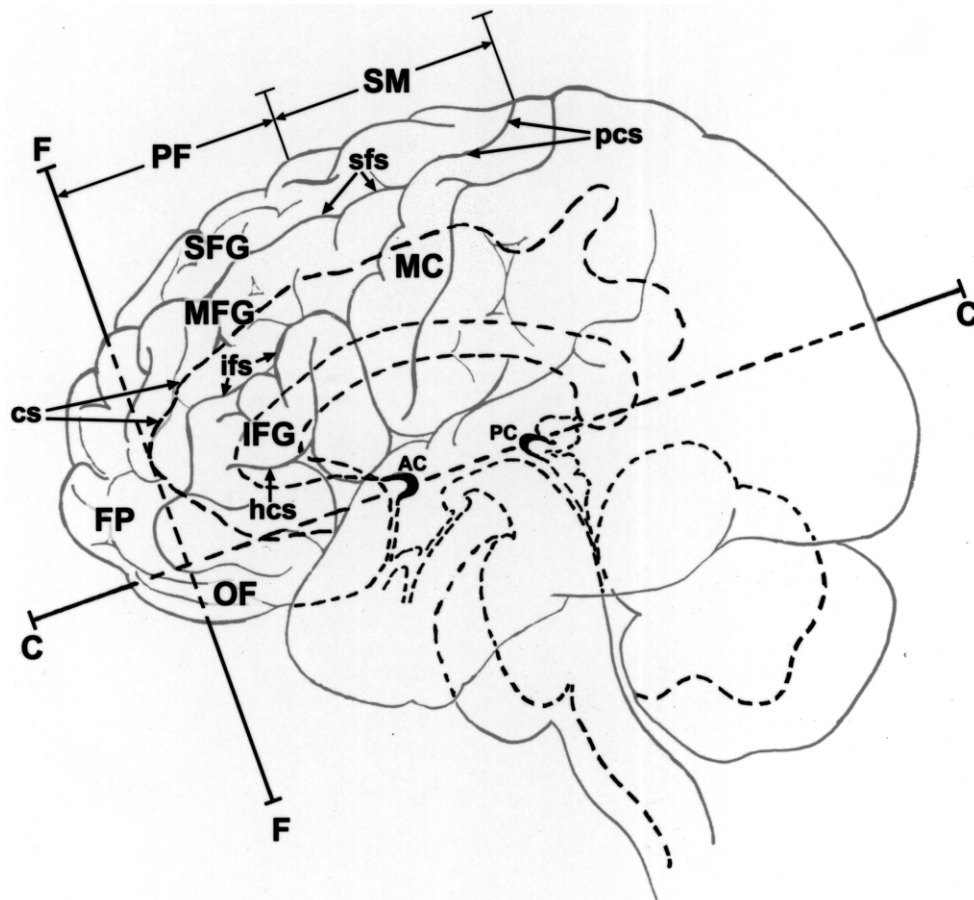


Fig. 1. This figure displays a cartoon of the brain with the lateral surface drawn in gray and the mid-sagittal structures of interest drawn in black interrupted lines.

pre-frontal region and the motor strip on coronal orientation. The procedures we have developed are similar to those used to identify the central sulcus (Berger et al., 1990). Specifically, we identify and mark the inferior frontal sulcus on lateral sagittal view. This sulcus is immediately superior to the easily identified frontal operculum. The inferior frontal sulcus, when continuous, joins directly

at its posterior end with the pre-central sulcus. As seen in the figures, the pre-central sulcus (pcs, Fig. 1 and panel C in Fig. 2) and the inferior frontal sulcus (ifs, see panel C in Fig. 2) are readily identifiable on lateral sagittal view. Similarly, the superior frontal sulcus (sfs, see panel A in Fig. 2) can be readily identified on axial view. The superior and inferior frontal sulci run approximately perpendicular to the

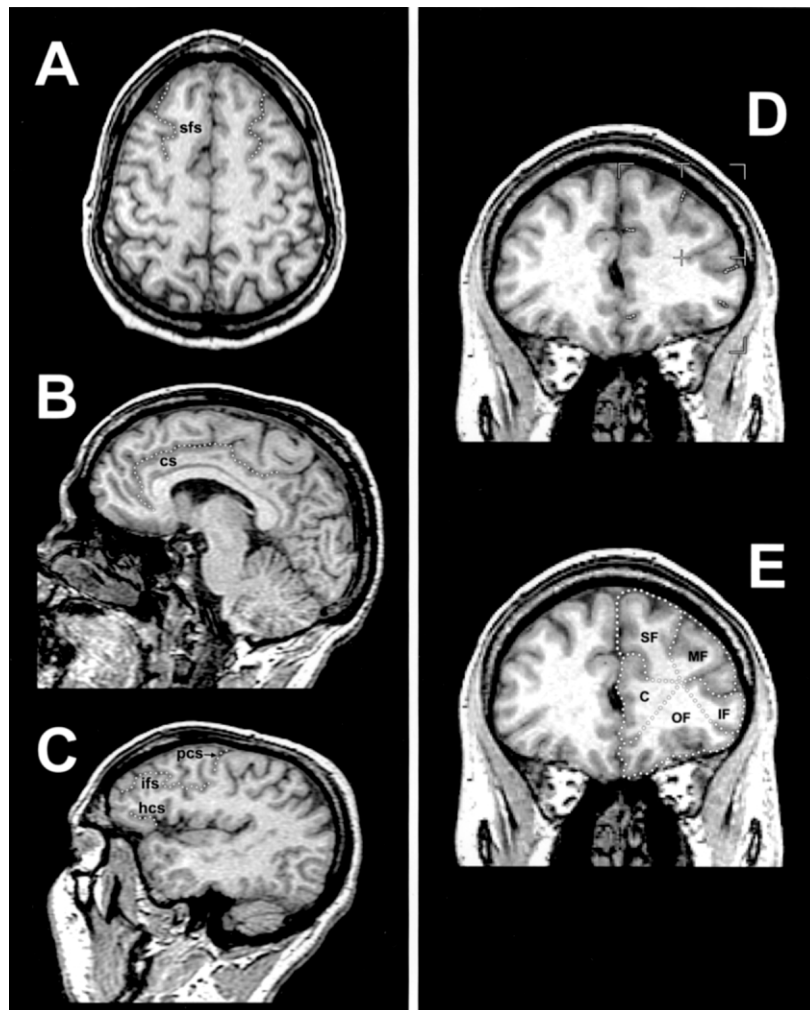


Fig. 2. Panel A is an axial MRI image on which the superior frontal sulcus (SFS) has been outlined; on panel B a representative mid-sagittal slice is displayed with the cingulate sulcus (CS) outlined; on panel C the pre-central sulcus (PCS) and the inferior frontal sulcus (IFS) and horizontal extension of the circular sulcus (HCS) have been outlined. The right hand panels display a coronal section used for the volume measurements. Panel D displays the marking retained from the axial and sagittal orientations as well as the geometric center anchor point. Panel E shows the actual drawings originating at the anchor point and utilizing the retained markings to delineate the frontal regions of interest (ROIs).

course of the precentral sulcus and, in most cases, intersect it. The lateral boundary of the orbito-frontal region is also difficult to ascertain on coronal orientation. On lateral sagittal views the horizontal extension of the circular sulcus (hcs, also called the anterior horizontal ramus of the Sylvian fissure) is readily seen (see panel C in Fig. 2), and can be used to identify the lateral boundary of the orbito-frontal (OF) region. In addition, on mid-sagittal view the cingulate sulcus (cs) is readily seen (see panel B in Fig. 2) and marked.

- **Creation of a standard coronal image for volume measurements:** we have shown that shifts in the plane of section of only a few degrees can give rise to differences in the spatial relationships between anatomical landmarks (Convit et al., 1999). Consequently, it is important to have very tight control over the plane of section used for volume measurements. To this end, from the 1.2-mm-thick sagittal SPGR scan, we created a set of reformatted coronal images, with a thickness of 2 mm, orthogonal to an axial plane through the anterior and posterior commissures (AC and PC, respectively). The AC and PC are identified on the mid-sagittal plane for each subject. In Fig. 1 the line CC represents the axial plane through the AC and PC and the line FF represents the coronal plane used for volume measurements. In Fig. 1 the FF plane is shown going through the cingulate sulcus (cs).
- **Transpose markings from SPGR sagittal and reformatted axial images to the reformatted coronal images used for volume measurements:** using Multimodal Image Data Analysis System (MIDAS) (Tsui, 1995), we can visualize markings made on one image orientation to another image orientation when the images are linked (derived from one another or registered). The reformatted axial and coronal images created from the original sagittal SPGR data are electronically linked to it. We identify the superior frontal sulcus on the axial image (Fig. 2, panel A) and the inferior frontal sulcus on the lateral sagittal image (Fig. 2, panel

C) and then transpose those markings to the coronal reformatted images created for the volume measurements (Fig. 2, panel D). Thus, we have a good guide to the gyrification, which allows reliable measurement of frontal lobe regions.

- **Define an ‘anchor point’ and then create the regions of interest (ROIs):** for each reformatted coronal image containing the anatomy of interest, separately for each hemisphere, we identify an anchor point, from which all ROIs will originate as spokes on a wheel. The anchor point is the geometric center of each hemisphere. The anchor point is defined by the intersection of vertical and horizontal lines that bisect the width and height of each hemisphere (refer to Fig. 2, panel D). This anchor point, which is represented as a cross-hair on Fig. 2, panel D, is then used as the origin of all ROIs (seen on Fig. 2, panel E). The ROIs are created by drawing radial lines from this anchor point to the deepest portion of each sulcus and then extended to the surface of the brain to define the gyri. We have used this anchor point technique for separating temporal lobe gyri (Convit et al., 1997) and observed that it leads to high reliability in their volume measurement, probably by standardizing the amount of white matter that is assigned to each gyrus.

### 2.3. Image analysis

Anatomical measurements were performed on a graphic workstation (Sun Microsystems Sparc) with a UNIX operating system using the Multimodal Image Data Analysis System (MIDAS) (Tsui, 1995). The ROIs were drawn on each of the slices in the set of coronal slices selected, and volumes were calculated by multiplying the total pixel counts by the pixel volume.

To correct for head size variations across individuals, we obtained a cranial vault volume by measuring the volume of the compartment between the dura and the tentorium. Every fifth



sagittal image (mid-points every 6 mm) was used to trace the outline of the supratentorial compartment by following the dural and tentorial margins.

#### 2.4. Subjects

In order to investigate whether the volumes of frontal lobe sub-regions are affected in schizophrenia or normal aging, we contrasted nine normal young men with nine normal elderly male subjects and with nine schizophrenic male subjects matched in age to the young normal group. We only studied men given the differential degree of age-related atrophy that has been reported by gender among normal individuals (Coffey et al., 1998; Resnick et al., 2000). In addition, all of our schizophrenic subjects were male. Future efforts will focus specifically on women. Normal young and old subjects were recruited through the Neuroimaging Laboratory of the Center for Brain Health of the NYU School of Medicine. Schizophrenic subjects were studied as part of a larger study conducted at the Kirby Forensic Psychiatric Center in New York. All subjects underwent a thorough screening protocol, which contained medical, neurological, psychiatric and neuropsychological evaluations. In order to ensure that we were able to ascertain age-related differences in frontal volumes between the two groups of normal individuals, we excluded subjects that had other conditions that could affect their brain. Also excluded among the young and older normal individuals were those subjects with current or past history of psychi-

atric, neurological or endocrine disorders. All schizophrenic subjects met DSM-IV (American Psychiatric Association, 1994) criteria for dual diagnosis of schizophrenia and either alcohol, cocaine or cannabis abuse or dependence. However, they met all other medical and MRI inclusion and exclusion criteria. All subjects gave written informed consent and were compensated for their time.

The demographic characteristics of the subjects are shown in Table 2. The schizophrenic group had significantly fewer years of formal education and also had a greater proportion of minority members.

#### 2.5. Statistics

We assessed the reproducibility of our method by having two raters independently draw the frontal lobe regions on one hemisphere of five young individuals who were not part of the current age comparison. Reliability estimates were determined both for the total volume and for the individual slice using intraclass correlation coefficient for fixed raters ( $r_{icc}$ ) (Shrout and Fleiss, 1979). In order to ascertain the impact of schizophrenia or normal aging on the frontal lobe volumes, we contrasted the MRI-derived volumes for the three groups by means of ANOVAs (with group membership as the grouping variable) and ANCOVAs (with cerebral vault size alone or cerebral vault size and education as covariates). Post-hoc testing of significant results was performed using the Scheffé post-hoc test.

Table 2  
Demographic characteristics of the subjects

	Young ( <i>n</i> = 9)	Schizophrenic ( <i>n</i> = 9)	Old ( <i>n</i> = 9)
Age	37.44 ± 8.41 (30–52)	35.00 ± 7.18 (25–46)	69.78 ± 5.54 (58–76) <sup>b</sup>
Education	18.00 ± 2.24 (16–22)	12.11 ± 2.26 (10–17) <sup>a</sup>	16.1 ± 2.57 (12–18)
Ethnicity (AA/H/C)	(0/0/9)	(5/1/3)	(0/0/9)

Means ± S.D. (range), AA/H/C African-American/Hispanic/Caucasian.

<sup>a</sup>*P* < 0.05 compared with young and old subjects.

<sup>b</sup>*P* < 0.05 compared with young and schizophrenic subjects.

### 3. Results

We computed reliability utilizing interclass correlation coefficients for the total regional volumes ( $N = 5$ ) as well as for the more rigorous assessment of concordance at the level of the slices that made up those volumes ( $N = 53$ ). We obtained high reliability (ranging from 0.88 to 0.99) for all of the frontal regions (Table 3).

The results of the volumetric analysis are shown in Table 4. The three groups did not differ in cerebral vault size. The main effect for the total pre-frontal volume only tended to be significant ( $F_{2,24} = 2.8$ ,  $P < 0.10$ ). However, examining the gyral sub-divisions of the pre-frontal cortex showed that there was a significant group main effect for the superior frontal gyrus ( $F_{2,24} = 14.9$ ,  $P < 0.01$ ) and orbital frontal gyrus ( $F_{2,24} = 6.4$ ,  $P < 0.01$ ). Post-hoc testing indicated that schizophrenic and normal old subjects had significantly smaller superior frontal gyri and orbital frontal gyri compared with the young normal group. However, old and schizophrenic subjects did not differ from each another. No significant group main effects were observed for the middle frontal, inferior frontal or cingulate regions. Identical results were obtained when cerebral vault size or cerebral vault size and education were used as covariates in an ANCOVA model. All normal subjects were Caucasian. In order to assess whether race might have influenced our schizophrenic group, we conducted an additional Mann–Whitney  $U$ -test contrasting African/American vs. Caucasian within our schizophrenic

group. As anticipated, the cerebral vault volumes were identical. In addition, none of the measured pre-frontal regions differed between these groups (all  $P > 0.10$ ).

### 4. Discussion

We have shown that our MRI-based parcellation method is highly reliable and that it is useful in separating our three clinical groups. We demonstrated reductions in superior and inferior pre-frontal regions in both the aging brain as well as in schizophrenia. While both conditions are characterized by poor performance in frontal lobe mediated tasks, the two conditions have vastly different clinical pictures. The pathology underlying these reductions and their functional significance are both difficult to ascertain and likely different in these two conditions. For example, both of the affected regions have afferents from the dorsomedial nucleus of the thalamus, with the parvicellular portion enervating the dorsolateral region (superior frontal) and the magnocellular enervating the orbital region (Fuster, 1989; Pandya and Yeterian, 2000). Therefore, at this time it is not possible to ascertain whether this loss of volume is primary or results from decreased thalamic enervation. In addition, there is evidence among drug naïve schizophrenics suggesting that hypofrontality may result from distributed dysfunctional circuits (Andreasen et al., 1997). Clearly more research is needed in order to characterize differences and similarities in

Table 3  
Inter-rater reliability (intraclass correlation coefficients) for frontal regions

Region	$r_{icc}$ Whole volume ( $n = 5$ )	$r_{icc}$ Individual slice ( $n = 57$ )
Superior frontal gyrus	$r_{icc} = 0.99$	$r_{icc} = 0.99$
Middle frontal gyrus	$r_{icc} = 0.98$	$r_{icc} = 0.96$
Inferior frontal gyrus	$r_{icc} = 0.98$	$r_{icc} = 0.96$
Orbital frontal gyrus	$r_{icc} = 0.98$	$r_{icc} = 0.88$
Cingulate	$r_{icc} = 0.93$	$r_{icc} = 0.89$

Table 4  
MRI derived volumes in young, schizophrenic and old subjects

Region	Young	Schizophrenic	Old
Superior frontal gyrus	35.3 ± 4.9	24.4 ± 5.6 <sup>a</sup>	25.7 ± 2.9 <sup>a</sup>
Middle frontal gyrus	23.4 ± 3.6	21.9 ± 5.2	21.4 ± 2.8
Inferior frontal gyrus	19.3 ± 3.1	18.2 ± 5.0	21.5 ± 2.8
Orbital frontal gyrus	40.1 ± 2.5	33.6 ± 6.4 <sup>a</sup>	34.3 ± 2.7 <sup>a</sup>
Cingulate	15.3 ± 2.7	14.9 ± 3.3	15.4 ± 2.1
Total prefrontal cortex	135.3 ± 8.1	116.8 ± 25.9	122.4 ± 11.1
Cerebral vault size	1285.0 ± 78.8	1296.8 ± 131.1	1291.2 ± 84.4

Means ± S.D.

<sup>a</sup> $P < 0.05$  compared with young subjects.

frontal lobe pathology occurring during aging and schizophrenia.

We have demonstrated that after controlling for cerebral vault size, both normal elderly subjects and schizophrenic subjects had significantly smaller superior frontal gyri and orbito-frontal regions than the young normal individuals matched in age to the schizophrenic group. However, these findings, particularly those in the schizophrenic group, need to be interpreted cautiously given higher educational achievement of the young normal group and the high prevalence of alcohol and substance abuse among our schizophrenic inpatients. None of the young or elderly normal subjects had histories of substance abuse, which prevented addressing this factor in the comparisons. To the best of our knowledge, there is only one previous MRI study of normal aging and two of schizophrenia that divided the frontal cortex into sub-regions and that had positive findings. Raz et al. (1997) observed age-associated decreases in orbital frontal and dorsolateral frontal regions, while seeing no changes in the anterior cingulate. In the schizophrenia studies, one group described differences in the surface area of the gyrus rectus and orbital region between normal and schizophrenic subjects, but did not find differences in the actual volumes of those regions (Crespo-Facorro et al., 2000). A second group reported a selective decrease in the inferior frontal region (Buchanan et al., 1998). Although we did not find a significant reduction

for the inferior frontal gyrus region, our orbitofrontal region extends laterally to the horizontal ramus of the circular sulcus, which has some degree of overlap with the inferior prefrontal region as defined by Buchanan et al. (1998). Our current findings highlight the value of separately assessing the superior, middle and inferior frontal gyri.

Our data of age-associated decreases of specific frontal lobe sub-regions are in line with previous studies demonstrating a substantial decrease in total frontal lobe volume as assessed with MRI (e.g. Coffey et al., 1992, 1998; Wahlund et al., 1990, 1996). Our parcellation method confirms those previous reports. We found that only the superior frontal gyrus and the orbital region were significantly smaller among elderly individuals relative to young controls. To our knowledge, this is the first report of such an observation.

Our pilot data demonstrate the usefulness of this new method for frontal lobe sub-volume analysis. By standardizing the angle of the coronal section and utilizing a clearly operationalized method for separating the supplementary motor region from the pre-frontal regions of interest, we hope that in future work our method will help to reduce the variability of measurement that has hindered previous literature. In the past we have used neuropathological validation of our sampling strategies by utilizing post-mortem MRI (Bobinski et al., 1999, 2000). In the future we intend to carry out a validation of this frontal lobe parcellation method.

## Acknowledgements

This work was, in part, supported by grants MH 44762, AG12101, AG17115, Deutsche Forschungsgesellschaft WO 733/1-1 and the New York State Office of Mental Health.

## References

- American Psychiatric Association, 1994. Diagnostic and Statistical Manual of Mental Disorders, 4th edition. American Psychiatric Press, Washington, D.C.
- Andreasen, N.C., Nasrallah, H.A., Dunn, V.D., Olson, S.C., Grove, W.M., Ehrhardt, J.C., Coffman, J.A., Crossett, J.H., 1986. Structural abnormalities in the frontal system in schizophrenia: a magnetic resonance imaging study. *Archives of General Psychiatry* 43, 136–144.
- Andreasen, N.C., O'Leary, D.S., Flaum, M., Nopoulos, P., Watkins, G.L., Boles Ponto, L.L., Hichwa, R.D., 1997. Hypofrontality in schizophrenia: distributed dysfunctional circuits in neuroleptic-naïve patients. *Lancet* 349, 1730–1734.
- Baare, W.F., Hulshoff Pol, H.E., Hijman, R., Mali, W.P., Wiergever, M.A., Kahn, R.S., 1999. Volumetric analysis of frontal lobe regions in schizophrenia: relation to cognitive dysfunction and symptomatology. *Biological Psychiatry* 45, 1597–1605.
- Berger, M.S., Cohen, W.A., Ojemann, G.A., 1990. Correlation of motor cortex brain mapping data with magnetic resonance imaging. *Journal of Neurosurgery* 72, 383–387.
- Berryhill, P., Lilly, M.A., Levin, H.S., Hillman, G.R., Mendelson, D., Brunder, D.G., Fletcher, J.M., Kufera, J., Kemt, T.A., Yeakley, J., 1995. Frontal lobe changes after severe diffuse closed head injury in children: a volumetric study of magnetic resonance imaging. *Neurosurgery* 37, 392–399.
- Bobinski, M., de Leon, M.J., Convit, A., De Santi, S., Wegiel, J., Tarshish, C.Y., Saint-Louis, L.A., Wisniewski, H.H., 1999. MRI of entorhinal cortex in mild Alzheimer's disease. *Lancet* 353, 38–40.
- Bobinski, M., de Leon, M.J., Wegiel, J., De Santi, S., Convit, A., Wisniewski, H.M., 2000. The histologic validation of MRI hippocampal volume measurements in Alzheimer disease. *Neuroscience* 95, 721–725.
- Breier, A., Buchanan, R.W., Elkashef, A., Munson, R.C., Kirkpatrick, B., Gellad, F., 1992. Brain morphology and schizophrenia: a magnetic resonance imaging study of limbic, prefrontal cortex, and caudate structures. *Archives of General Psychiatry* 49, 921–926.
- Brodman, K., 1909. Vergleichende Lokalisationslehre der Grosshirnrinde in Ihren Prinzipien Dargestellt auf Grund des Zellenbaues. Barth, Leipzig.
- Buchanan, R.W., Vadar, K., Barta, P.E., Pearlson, G.D., 1998. Structural evaluation of the prefrontal cortex in schizophrenia. *American Journal of Psychiatry* 155, 1049–1055.
- Buckley, P.F., 1998. Structural brain imaging in schizophrenia. *Psychiatric Clinics of North America* 21, 77–92.
- Bunney, B.G., Potkin, S.G., Bunney, W.E., 1997. Neuropathological studies of brain tissue in schizophrenia. *Journal of Psychiatric Research* 31, 159–173.
- Coffey, C.E., Figiel, G.S., Djang, W.T., Weiner, R.D., 1990. Subcortical hypertension on magnetic imaging: a comparison of normal and depressed elderly subjects. *American Journal of Psychiatry* 147, 187–189.
- Coffey, C.E., Lucke, J.F., Saxton, J.A., Ratcliff, G., Unitas, L.J., Billig, B., Bryan, R.N., 1998. Sex differences in brain aging: a quantitative magnetic resonance imaging study. *Archives of Neurology* 55, 169–179.
- Coffey, C.E., Wilkinson, W.E., Parashos, I.A., Soady, S.A.R., Sullivan, R.J., Patterson, L.J., Figiel, G.S., Webb, M.C., Spritzer, C.E., Djang, W.T., 1992. Quantitative cerebral anatomy of the aging human brain: a cross-sectional study using magnetic resonance imaging. *Neurology* 42, 527–536.
- Convit, A., de Leon, M.J., Tarshish, C., De Santi, S., Tsui, W., Rusinek, H., George, A.E., 1997. Specific hippocampal volume reductions in individuals at risk for Alzheimer's disease. *Neurobiology of Aging* 18, 131–138.
- Convit, A., McHugh, P.R., Wolf, O.T., de Leon, M.J., Bobinski, M., De Santi, S., Roche, A., Tsui, W., 1999. MRI volume of the amygdala: a reliable method allowing separation from the hippocampal formation. *Psychiatry Research: Neuroimaging* 90, 113–123.
- Crespo-Facorro, B., Kim, J.J., Andreasen, N.C., O'Leary, D.S., Magnotta, V.A., 2000. Regional frontal abnormalities in schizophrenia: a quantitative gray matter volume and cortical surface size study. *Biological Psychiatry* 48, 110–119.
- Crespo-Facorro, B., Kim, J.J., Andreasen, N.C., O'Leary, D.S., Wiser, A.K., Bailey, J.M., Harris, G., Magnotta, V.A., 1999. Human frontal cortex: an MRI-based parcellation method. *Neuroimage* 10, 500–519.
- Duvernoy, H.M., 1991. *The Human Brain*. Springer-Verlag, Wien.
- Ebert, D., Ebmeier, K.P., 1996. The role of the cingulate gyrus in depression: from functional anatomy to neurochemistry. *Biological Psychiatry* 39, 1044–1050.
- Fazekas, F., Chawluk, J.B., Alavi, A., Hurtig, H.I., Zimmerman, R.A., 1987. MR signal abnormalities at 1.5 T in Alzheimer's dementia and normal aging. *American Journal of Roentgenology* 149, 351–356.
- Pfefferbaum, A., Sullivan, E.V., Rosenbloom, M.J., Mathalon, D.H., Lim, K.O., 1998. A controlled study of cortical gray matter and ventricular changes in alcoholic men over a 5-year period interval. *Archives of General Psychiatry* 55, 905–912.
- Fuster, J., 1989. *The Prefrontal Cortex: Anatomy, Physiology and Neuropsychology of the Frontal Lobes*, 2nd edition. Raven Press, New York.
- Goldman-Rakic, P.S., Selemon, L.D., 1997. Functional and anatomical aspects of prefrontal pathology in schizophrenia. *Schizophrenia Bulletin* 23, 437–458.
- Goodwin, G.M., 1997. Neuropsychological and neuroimaging

- evidence for the involvement of the frontal lobes in depression. *Journal of Psychopharmacology* 11, 115–122.
- Iwasaki, S., Nakagawa, H., Fukusumi, A., Kichikawa, K., Kitamura, K., Otsuji, H., Uchida, H., Ohishi, H., Yaguchi, K., Sumie, H., Kuru, Y., 1991. Identification of pre- and post-central gyri on CT and MR images on the basis of the medullary pattern of cerebral white matter. *Radiology* 179, 207–213.
- Lai, T.-J., Payne, M.E., Byrum, C.E., Steffens, D.C., Krishnan, K.R.R., 2000. Reduction of orbital frontal cortex volume in geriatric depression. *Biological Psychiatry* 48, 971–975.
- Lawrie, S.M., Abukmeil, S.S., 1998. Brain abnormality in schizophrenia: a systematic and quantitative review of volumetric magnetic resonance imaging studies. *British Journal of Psychiatry* 172, 110–120.
- Levin, H.S., Eisenberg, H.M., Benton, A.L., 1991. *Frontal Lobe Function and Dysfunction*. Oxford University Press, New York, Oxford.
- Malloy, P.F., Richardson, E.D., 1994. Assessment of frontal lobe functions. *Journal of Neuropsychiatry and Clinical Neurosciences* 6, 399–410.
- McCarley, R.W., Wible, C., Frumin, M., Hirayasu, Y., Levitt, J.J., Fischer, I.A., Shenton, M.E., 1999. MRI anatomy of schizophrenia. *Biological Psychiatry* 45, 1099–1119.
- Ono, M., Kublik, S., Abernathey, C.D., 1990. *Atlas of the Cerebral Sulci*. Thieme Medical Publishers, Inc, New York.
- Pandya, D.N., Yeterian, E.H., 2000. Prefrontal cortex in relation to other cortical areas in rhesus monkey: architecture and connections. *Progress in Brain Research* 85, 63–94.
- Pearlson, G.D., Marsh, L., 1999. Structural brain imaging in schizophrenia: a selective review. *Biological Psychiatry* 46, 627–649.
- Rademacher, J., Galaburda, A.M., Kennedy, D.N., Filipek, P.A., Caviness Jr., V.S., 1992. Human cerebral cortex: localization, parcellation, and morphometry with magnetic resonance imaging. *Journal of Cognitive Neuroscience* 4 (4).
- Raine, A., Lencz, T., Reynolds, G.P., Harrison, G., Sheard, C., Medley, I., Reynolds, L.M., Cooper, J.E., 1992. An evaluation of structural and functional prefrontal deficits in schizophrenia: MRI and neuropsychological measures. *Psychiatry Research: Neuroimaging* 45, 123–137.
- Raz, N., Gunning, F.M., Head, D., Dupuis, J.H., McQuain, J., Briggs, S.D., Loken, W.J., Thornton, A.E., Acker, J.D., 1997. Selective aging of the human cerebral cortex observed in vivo: differential vulnerability of the prefrontal gray matter. *Cerebral Cortex* 7, 268–282.
- Resnick, S.M., Goldszal, A.F., Davatzikos, C., Golski, S., Kraut, M.A., Metter, E.J., Bryan, R.N., Zonderman, A.B., 2000. One-year age changes in MRI brain volumes in older adults. *Cerebral Cortex* 10, 464–472. Ref. type: generic
- Semendeferi, K., Damasio, H., Frank, R., van Hoesen, G.W., 1997. The evolution of the frontal lobes: a volumetric analysis based on three-dimensional reconstructions of magnetic resonance scans of human and ape brain. *Journal of Human Evolution* 32, 375–388.
- Shrout, P.E., Fleiss, J.L., 1979. Intraclass correlations: uses in assessing rater reliability. *Psychological Bulletin* 86, 420–428.
- Smith, E.E., Jonides, J., 1998. Neuroimaging analyses of human working memory. *Proceedings of the National Academy of Sciences of the United States of America* 95, 12061–12068.
- Smith, E.E., Jonides, J., 1999. Storage and executive processes in the frontal lobes. *Science* 283, 1657–1661.
- Stuss, D.T., Benson, D.F., 1986. *Frontal Motor Function. The Frontal Lobes*. Raven Press, New York, pp. 73–96.
- Szeszko, P.R., Bilder, R.M., Lencz, T., Pollack, S., Alvir, J.M., Ashtari, M., Wu, H., Lieberman, J.A., 1999. Investigation of frontal lobe subregions in first-episode schizophrenia. *Psychiatry Research: Neuroimaging* 90, 1–15.
- Tsui, W.H. 1995. Multimodal Image Data Analysis System (MIDAS), Version 1.0. 1995. Unpublished Work.
- Uylings, H.B., Van Eden, C.G., 1990. Qualitative and quantitative comparison of the prefrontal cortex in rat and in primates, including humans. *Progress in Brain Research* 85, 31–62.
- Velligan, D.I., Bow-Thomas, C.C., 1999. Executive function in schizophrenia. *Seminars in Clinical Neuropsychiatry* 4, 24–33.
- Wahlund, L.-O., Agartz, I., Almqvist, O., Basun, H., Forssell, L., Saaf, J., Wetterberg, L., 1990. The brain in healthy aged individuals: MR imaging. *Neuroradiology* 174, 675–677.
- Wahlund, L.-O., Almqvist, O., Basun, H., Julin, P., 1996. MRI in successful aging, a 5-year follow-up study from the eighth to ninth decade of life. *Magnetic Resonance Imaging* 14, 601–608.
- Weinberger, D.R., Berman, K.F., Zec, R.F., 1986. Physiological dysfunction of dorsolateral prefrontal cortex in schizophrenia: I. Regional cerebral blood flow (rCBF) evidence. *Archives of General Psychiatry* 43, 114–124.
- West, R.L., 1996. An application of prefrontal cortex function theory to cognitive aging. *Psychological Bulletin* 120, 272–292.
- Wible, C.G., Shenton, M.E., Fischer, I.A., Allard, J.E., Kikinis, R., Jolesz, F.A., Iosifescu, D.V., McCarley, R.W., 1997. Parcellation of the human prefrontal cortex using MRI. *Psychiatry Research: Neuroimaging* 76, 29–40.
- Wright, I.C., Rabe-Hesketh, S., Woodruff, P.W.R., David, S.A., Murray, R.M., Bullmore, E., 2000. Meta-analysis of regional brain volumes in schizophrenia. *American Journal of Psychiatry* 157, 16–25.
- Woods, B.T., Yrgelund-Todd, D., Golstein, J.M., Seidman, L.J., Tsuang, M.T., 1996. MRI brain abnormalities in chronic schizophrenia: one process or more? *Biological Psychiatry* 40, 585–596.